

See discussions, stats, and author profiles for this publication at: <https://www.researchgate.net/publication/319134848>

# Role of therapeutic fasting along with other Naturopathy and Yoga Modalities in addressing

Article · August 2017

DOI: 10.22038/JFH.2017.25098.1093

---

CITATION

1

READS

215

2 authors, including:



**Pradeep MK Nair**

Indian Academy for Scientific Writing and Research

24 PUBLICATIONS 58 CITATIONS

SEE PROFILE

Some of the authors of this publication are also working on these related projects:



Clinical Naturopathy: A manual for physicans and students [View project](#)



Tuberculosis [View project](#)

# Role of Therapeutic Fasting along with Other Naturopathy and Yoga Modalities in Addressing Acne Vulgaris – A single Case Report

Pushparaj Ameya<sup>1</sup>, Pradeep MK Nair<sup>2\*</sup>

1. BNYS Senior Medical Officer, Nisargopachar Ashram, Urulikanchan Pune, India
2. BNYS, MSc (Clinical Research), Senior Medical Officer, Department of Intramural Research, National Institute of Naturopathy, Ministry of AYUSH, Government of India, Pune, India

| ARTICLE INFO  | ABSTRACT   |
|---|--|
| <p><i>Article type:</i><br/>Case Report</p> <hr/> <p><i>Article History:</i><br/>Received: 21 Jul 2017<br/>Accepted: 18 Aug 2017<br/>Published: 20 Sep 2017</p> <hr/> <p><i>Keywords:</i><br/>Acne vulgaris<br/>Inflammation<br/>Naturopathy<br/>Skin care<br/>Therapeutic fasting<br/>Yoga</p> | <p>A 23 year old female diagnosed as acne vulgaris underwent Therapeutic fasting (TF) and other naturopathy and yoga modalities for 30 days. She presented with eruptions all over her face and the face was edematous. She was given a modified diet for initial 3 days which included fresh fruits and juices along with cooked vegetables and sorghum roti. Additionally Naturopathy treatments like Swedish massage, steam bath, warm water enema and hip bath were given along with some yogic postures, pranayam and kriyas (Cleansing procedures). The patient responded well to the therapeutic fasting. By the end of 30 days there were no eruptions in her face and her skin also was clear. All the treatments were based on the principle of naturopathic medicine that the body has its own power to heal itself. TF has shown to attenuate inflammatory status of the body by suppressing pro-inflammatory cytokine expression and decreasing body fat and circulating levels of leukocytes. This is the first study to report the non pharmacological approach towards treating acne. To conclude fasting along with other naturopathy and yoga modalities has shown noteworthy changes in reducing the inflammatory response in acne vulgaris. However large scale studies are warranted.</p> |

► Please cite this paper as:

Ameya P, Nair PMK. Role of Therapeutic Fasting along with Other Naturopathy and Yoga Modalities in Addressing Acne Vulgaris – A single Case Report. J Fasting Health. 2017; 5(3): 103-106. DOI: 10.22038/jfh.2017.25098.1093

## Introduction

Acne by definition is multifactorial chronic inflammatory disease of pilosebaceous units and is one of the most common disorders treated by dermatologists and other health care providers (1). It is commonly seen among adolescents and to some extent seen in adults and children also (2). In recent years, due to better understanding of the pathogenesis of acne, new therapeutic modalities are designed and used by the patients (3). There is a sheer interest in complementary and alternative medicine (CAM) over the past decade and the general public is showing a positive attitude towards CAM therapies (4). Therapeutic fasting (TF) is one of the common modality used by naturopathic physicians to treat various types of acute and

chronic diseases. However there is no report on use of the TF to treat acne vulgaris. Here we report the prognosis of our patient who underwent TF along with other naturopathic and yogic modalities for acne vulgaris.

## Case Presentation

A 23 year old female got admitted to our inpatient department at Urulikanchan, Pune on July 2015 diagnosed with nodular acne vulgaris as per ICD-10-CM L70.0 (5). She presented with eruptions all over her face and the face was edematous. She has been diagnosed as acne vulgaris for the past six months. She had tried many topical applications before opting for Naturopathy, but there was no improvement in

\* Corresponding author: Pradeep MK Nair, Department of Intramural Research, National Institute of Naturopathy, Ministry of AYUSH, Government of India, Pune, India. Email: drpradeep18bnys@gmail.com

© 2017 mums.ac.ir All rights reserved.

This is an Open Access article distributed under the terms of the Creative Commons Attribution License (<http://creativecommons.org/licenses/by/3.0>), which permits unrestricted use, distribution, and reproduction in any medium, provided the original work is properly cited.

the condition.

### **Therapeutic focus and assessment**

On admission our patient was given a detailed counseling about naturopathy and yoga, particularly about the TF in order to prepare her to undergo this fast along with other naturopathy and yoga modalities. A modified treatment protocol was designed by Ameya Pushparaj, who is having 8 years experience in administering TF and other naturopathy modalities. The patient was provided a diet plan which included Holy basil decoction, fresh carrot juice, mosambi Juice (sweet lime) along with a non spicy vegetable curry and bhakri (An Indian preparation with sorghum) for the first three days. She was advised to switch on to a fruit only diet from the third day where she had fresh fruits like water melon, pomegranate, mosambi and apple for the whole day. This was followed till 5<sup>th</sup> day.

From 6<sup>th</sup> day onwards she was alternated to TF, where she consumed only lemon honey juice and tender coconut water for the whole day. This period of fasting extended till the 16<sup>th</sup> day under proper supervision of the medical officer of the ashram. Her vitals like Blood Pressure, Pulse, and temperature were checked at an interval of 6 hours. The total fasting period was for 11 days after that she was shifted gradually back to the normal diet. Other than TF she also underwent a series of Naturopathy treatments like Swedish massage, steam bath, warm water enema and hip bath. The duration and dosage of the treatments are given in table 1. All these interventions were purported to heighten the healing mechanisms and induce relaxation

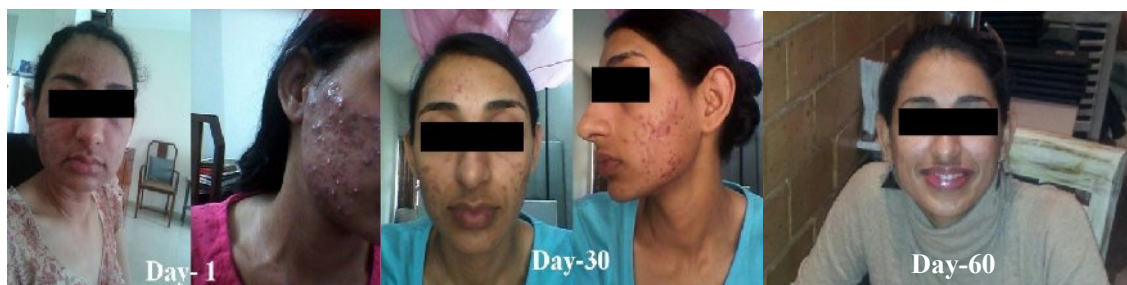**Table 1.** Naturopathy interventions dosage and Frequency

| Interventions | Duration   | Frequency      |
|---------------|------------|----------------|
| Massage       | 45 minutes | Daily          |
| Steam bath    | 7 minutes  | Alternate days |
| Enema         | --         | Alternate days |
| Hip bath      | 10 minutes | Daily          |

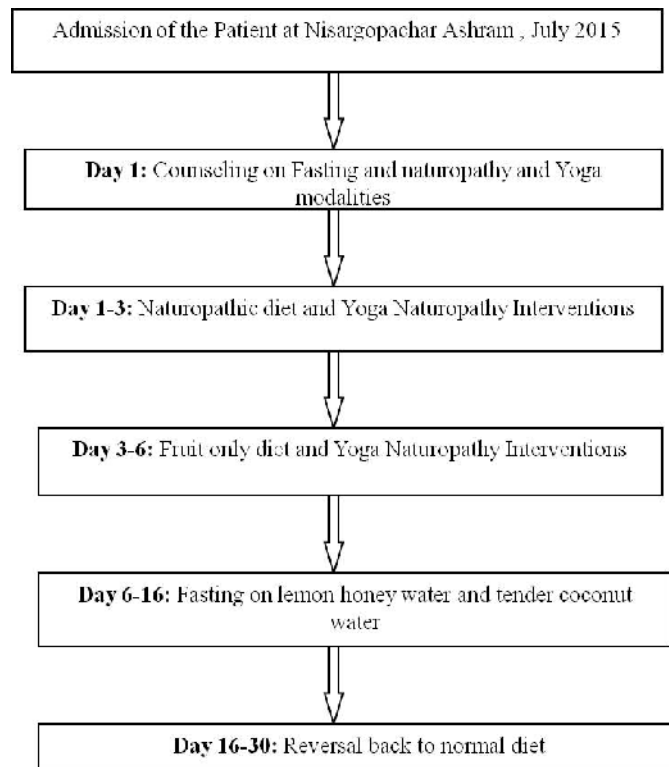
authors. Additionally our patient was asked to practice yoga everyday for 45 minutes, other than on fasting days. According to yoga philosophy, restoration of skin health is achieved primarily by influencing the digestive and circulatory functions (6). It included some specific yoga postures, breathing techniques and yogic kriyas (Cleansing procedures) like Bhujangasana, Halasana, Matsyasana, Sarvangasana, Nadishudhi pranayama, Brahmari Pranayama, Bhastrika Pranayama, vaman Dhouti, Jalneti, Kaphalpathi respectively. These interventions were based on the effect of yoga on Inflammation (7).

### **Follow up and outcomes**

Our patient showed marked improvement in her symptoms during the course of the treatment. The entire intervention was given for 30 days. There was considerable reduction in the eruptions and inflammation on her face. During 3<sup>rd</sup> day of fasting, 3- 4 new eruptions appeared which gradually disappeared during the course of fasting. At the end of her stay her skin was much clearer and there was no inflammation or swelling. The sequential changes are demonstrated in figure 1, 2 and 3 respectively. The patient does not express any sort of discomfort during the entire course of treatment. The entire timeline of this case is depicted in Figure 4. The patient was followed up for a month post intervention, but no relapse of symptoms was reported.



**Figure 1-3.** Changes in lesions across 60 days



**Figure 4.** Timeline of the intervention delivered

## Discussion

All the treatments were based on the principle of naturopathic medicine that the body has its own power to heal itself (8). Therapeutic Fasting is used as a first treatment of choice in naturopathic medicine (9). It has empirically documented beneficial effects on metabolic syndromes, chronic inflammatory disease, chronic cardiovascular disease, chronic pain syndromes, atopic diseases and psychosomatic illnesses (10). TF has shown to attenuate inflammatory status of the body by suppressing pro-inflammatory cytokine expression and decreasing body fat and circulating levels of leukocytes (11) which renders it to be a solid tool against inflammatory disorders. Naturopathy and yoga treatments basically provide a wholesome holistic approach towards a disease where the human is considered as a whole entity. In addition to fasting, hydrotherapy, massage and yoga modalities were also given to the patient to fillip her healing response. These modalities are known for its effect on removing the algogenic chemicals from the body (12), induce endorphin

secretion (13) and reduce inflammation (7). Additionally these therapies are collectively known to induce chemical, thermal, mechanical, and immunomodulatory effects in dermatological conditions (14). Incompatible dietary mannerisms and consumption of incompatible diets are termed as the causative factor for many skin diseases including acne (15). Kulakarni M et al. 2016 reported a higher consumption of incompatible diet and dietary habits in acne and psoriasis patients (16). Smith.RN et al. 2007 have observed similar effects after administration of low glycemic load diet and suggested a possible role of nutrition based lifestyle interventions in the pathogenesis of acne and insulin sensitivity (17). In this case, there was no relapse reported even after one month follow-up period, this may be due to the strict adherence to the dietary intake and patterns. Nevertheless TF can be used a potent option against the current dermatological applications which often elicit side effects ranging from dryness of skin, lips, eyes to atopic dermatitis (18).

Strengths and limitation of this study: The major strength of this study is its implication on lifestyle change as a non pharmacological remedy to treat acne vulgaris. However, this is a single case study whose results cannot be generalized which is one of the major limitations. It stresses the importance of future mechanistic studies in fasting with larger samples.

## Conclusion

Fasting along with other naturopathy and yoga modalities has shown noteworthy changes in reducing the inflammatory response in acne vulgaris as demonstrated in this case. As per our knowledge this is the first report of a non-pharmacological intervention in treating acne vulgaris. However large scale randomized control trials or observational studies with larger sample size should be conducted to fortify the current findings.

## Patient perspective

Our patient expressed high level of satisfaction with the results and there was no relapse of symptoms even during her cycles which she was complaining before. She finds therapeutic fasting as a practical and nature friendly solution for her skin eruptions.

## Patient consent

Written permission for publication of this case study and photographs had been obtained from the patient.

## Acknowledgments

The authors would like to thank Dr. Abhishek Devikar, Director, Nisargopachar Ashram and Dr.Hyndavi Salwa, Research officer, NIN, Pune for their support.

## References

1. Simpson NB, Cunliffe WJ. Disorders of the sebaceous glands. In: Burns T, Breathnach S, Cox N, Griffiths C, editors. Textbook of dermatology. 7<sup>th</sup> ed. New Jersey: Blackwell Science; 2004. P. 43-75.
2. Zaenglein AL, Pathy AL, Schlosser BJ, Alikhan A, Baldwin HE, Berson DS, et al. Guidelines of care for the management of acne vulgaris. *J Am Acad Dermatol.* 2016; 74:945-73.
3. Leyden JJ. New understanding of the pathogenesis of acne. *J Am Acad Dermatol.* 1995; 32(5):S15-25.
4. Frass M, Strassl RP, Friehs H, Müllner M, Kundi M, Kaye AD. Use and acceptance of complementary and alternative medicine among the general population and medical personnel: a systematic review. *Ochsner J.* 2012; 12(1):45-56.
5. World Health Organization. International classification of disease. Geneva: World Health Organization; 2017.
6. Mayer A, Indea AY. Yoga for skin diseases. India: Ananda Yoga Indea; 2013.
7. Kiecolt-Glaser JK, Bennett JM, Andridge R, Peng J, Shapiro CL, Malarkey WB, et al. Yoga's impact on inflammation, mood, and fatigue in breast cancer survivors: a randomized controlled trial. *J Clin Oncol.* 2014; 32(10):1040-9.
8. Nair PM, Nanda A. Naturopathic medicine in India. *Focus Altern Complement Ther.* 2014; 19(3):140-7.
9. Nair PM, Mohanty S. Knowledge, attitude and practice of therapeutic fasting among naturopathy physicians: a cross sectional national survey. *J Fasting Health.* 2015; 3(4):177-82.
10. Wilhelmi de Toledo F, Buchinger A, Burggrave H, Hölz G, Kuhn C, Lischka E, et al. Fasting therapy- an expert panel update of the 2002 consensus guidelines. *Forsch Komplementmed.* 2013; 20(6):434-43.
11. Faris MA, Kacimi S, Al-Kurd RA, Fararjeh MA, Bustanji YK, Mohammad MK, et al. Intermittent fasting during Ramadan attenuates proinflammatory cytokines and immune cells in healthy subjects. *Nutr Res.* 2012; 32(12):947-55.
12. Dhananjay A, Jincy S, Raghuraj P. Critical review on trends in hydrotherapy research. *Int J Naturop Med.* 2012; 6:693-6.
13. Goats GC. Massage-the scientific basis of an ancient art: part 2. Physiological and therapeutic effects. *Br J Sports Med.* 1994; 28(3):153-6.
14. Matz H, Orion E, Wolf R. Balneotherapy in dermatology. *Dermatol Ther.* 2003; 16(2):132-40.
15. Sharma PV. Charaka Samhita; Agnivesha's treatise refined and annotated by Charaka and redacted by Drudhbala (text with English translation). Jaikrishnadas Ayurveda Series. 2011; 4(36):85-7.
16. Kulkarni M, Keny D, Potey AV, Tripathi RK. A cross-sectional study to assess the incompatible dietary behavior of patients suffering from skin diseases: a pilot study. *J Ayurveda Integr Med.* 2016; 7(2):113-8.
17. Smith RN, Mann NJ, Braue A, Mäkeläinen H, Varigos GA. A low-glycemic-load diet improves symptoms in acne vulgaris patients: a randomized controlled trial. *Am J Clin Nutr.* 2007; 86(1):107-15.
18. Webster GF. Acne vulgaris. *BMJ.* 2002; 325 (7362):475-9.